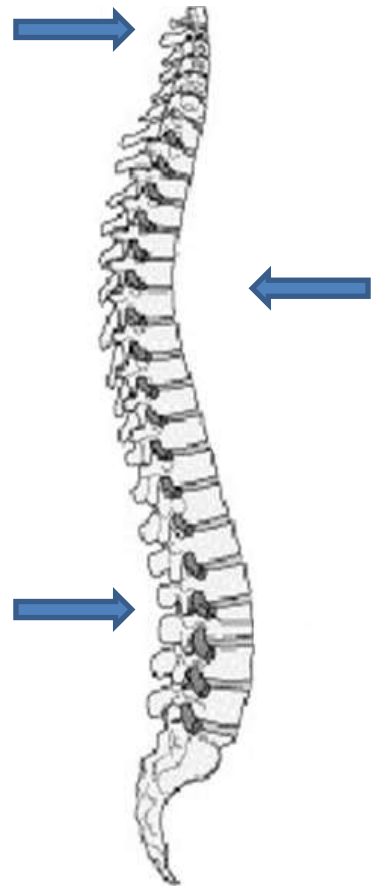
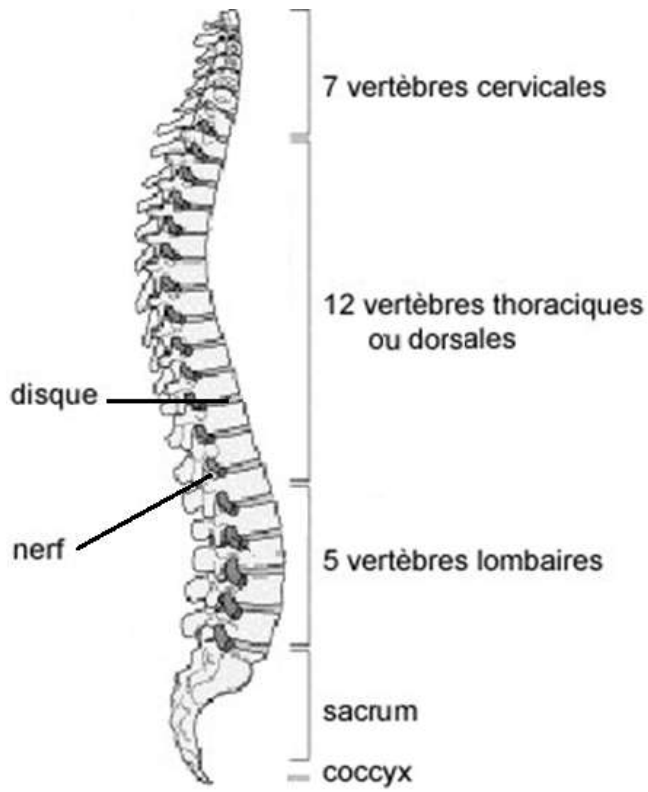
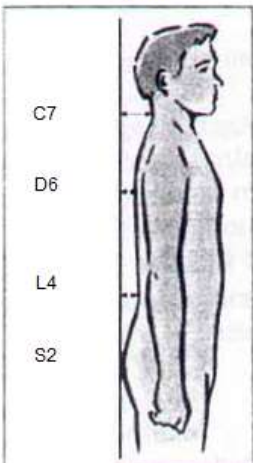


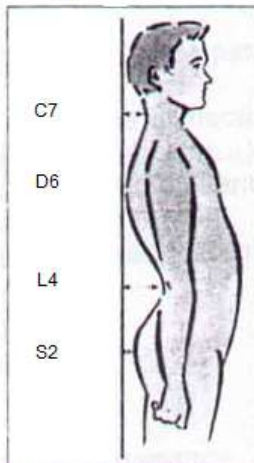
Université STAPS
Anatomie TD 12
Le rachis



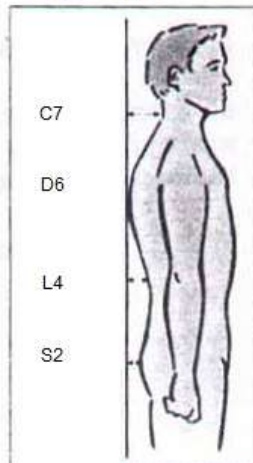
Dos plat



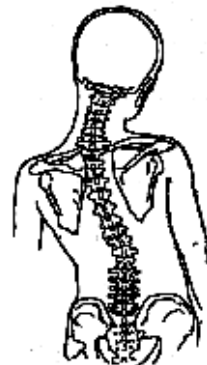
Hyperlordose



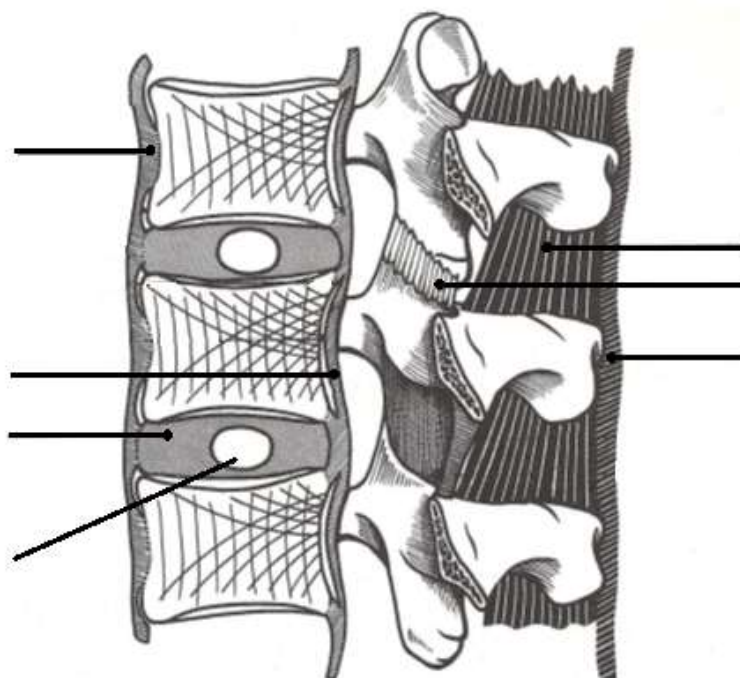
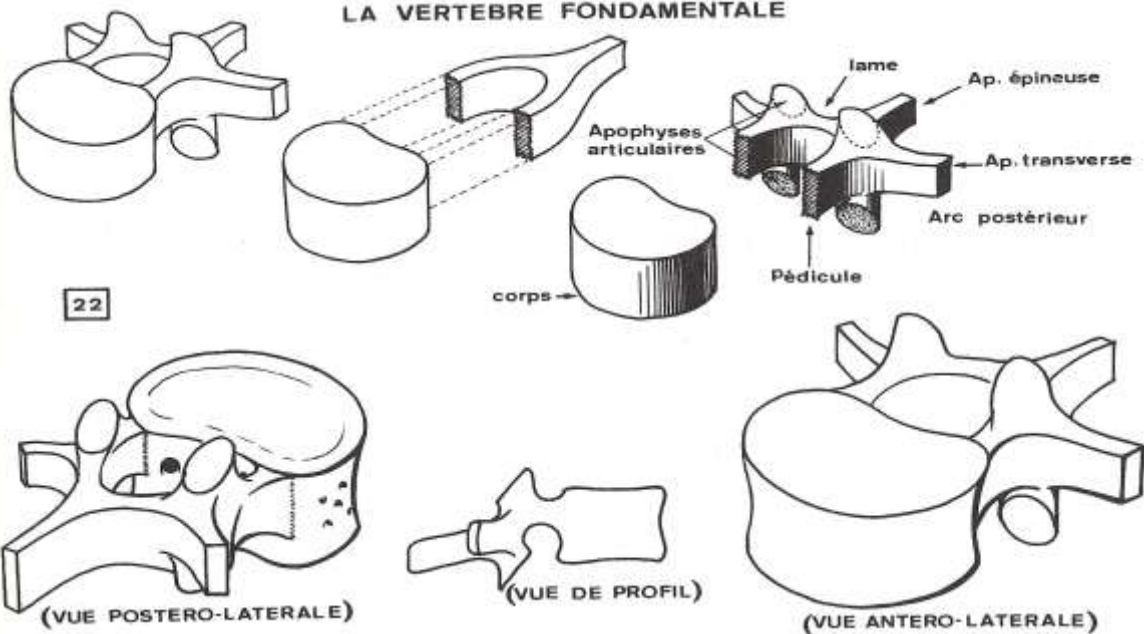
Hypercyphose



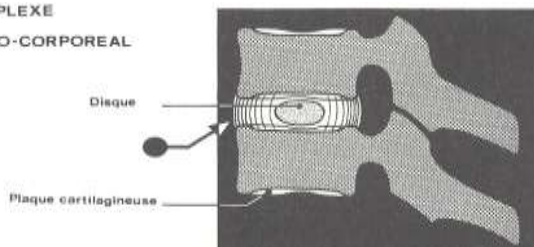
Scoliose



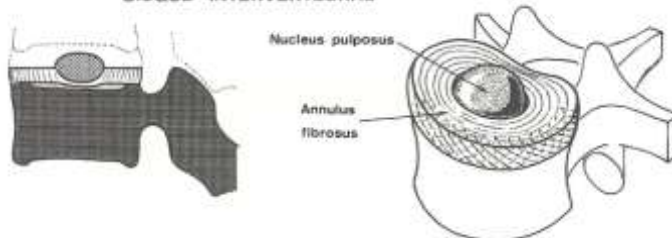
LA VERTEBRE FONDAMENTALE

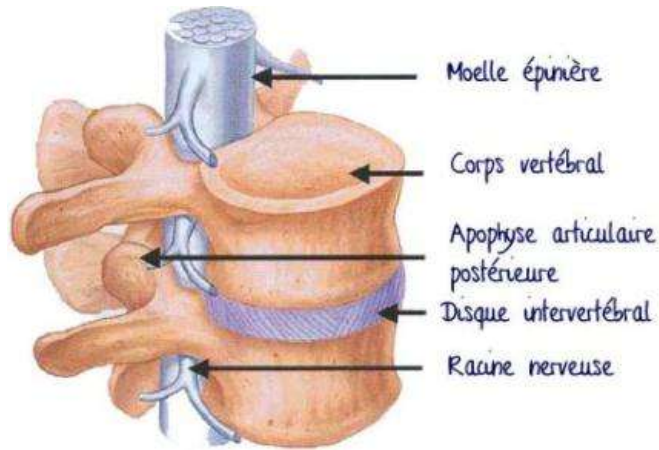


COMPLEXE DISCO-CORPOREAL

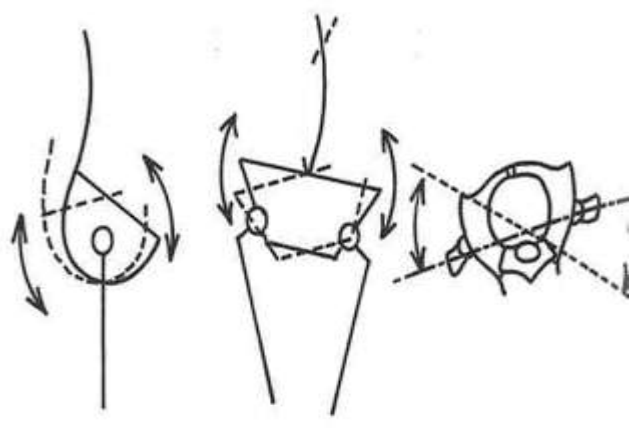

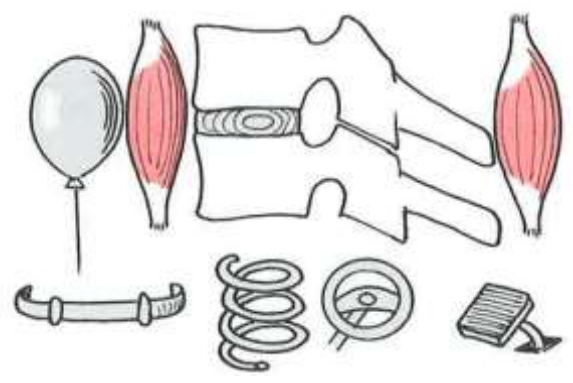
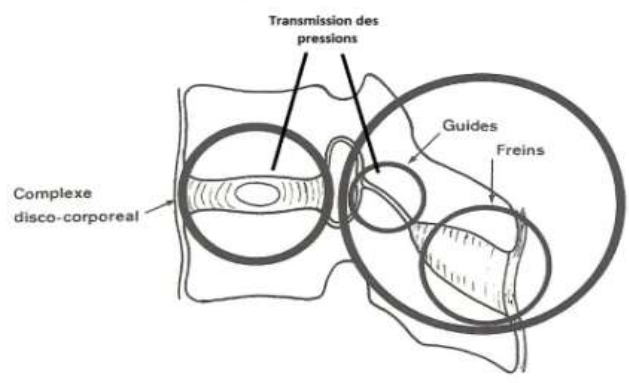
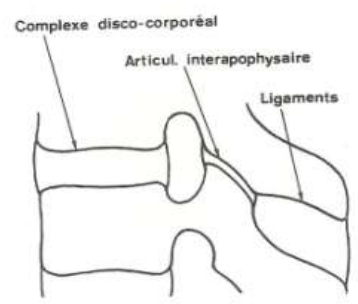
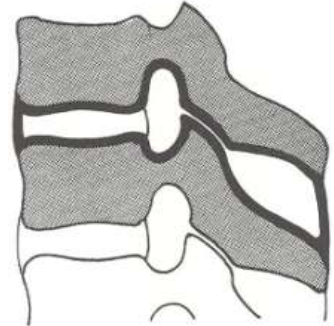


DISQUE INTERVERTEBRAL

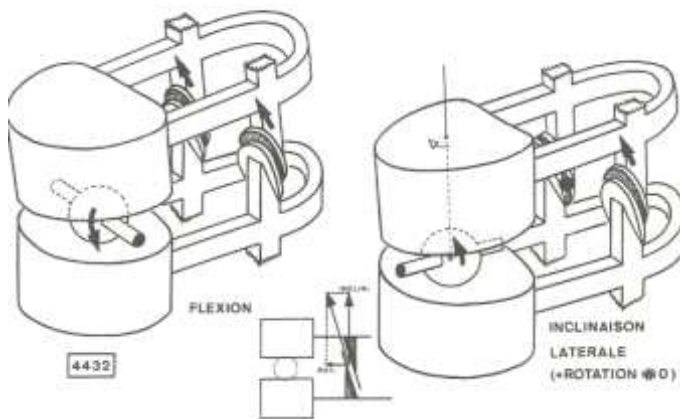
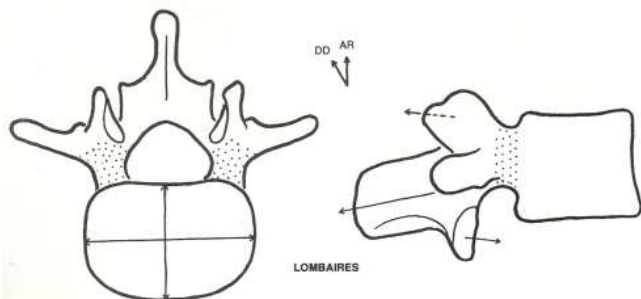
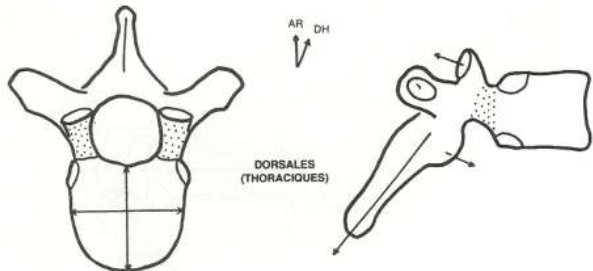
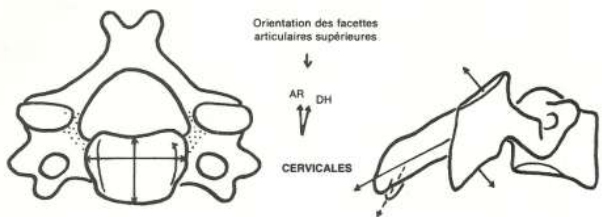




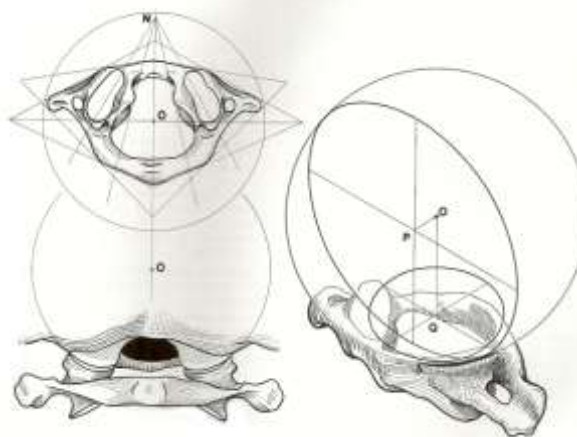
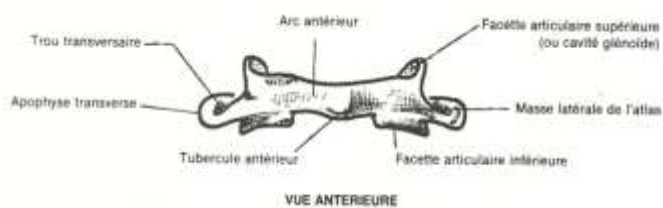
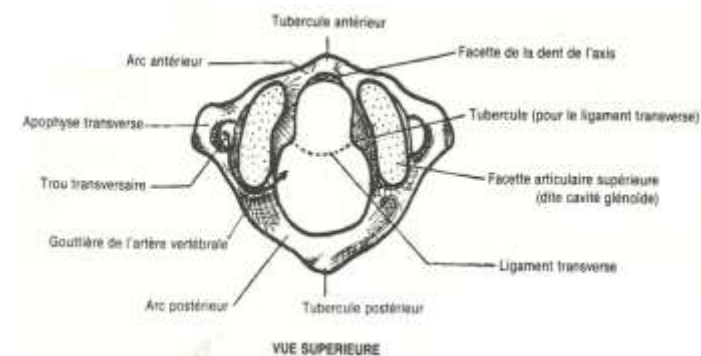
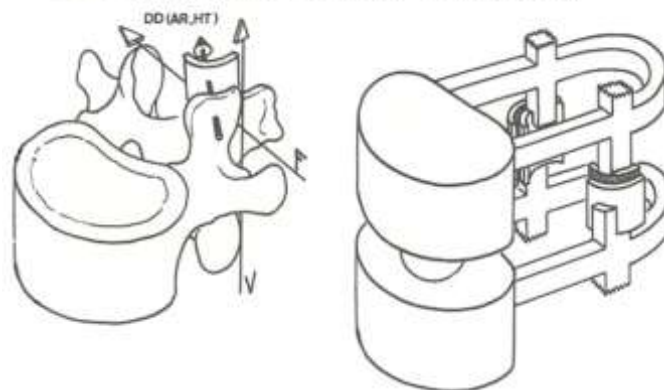
L'arthron



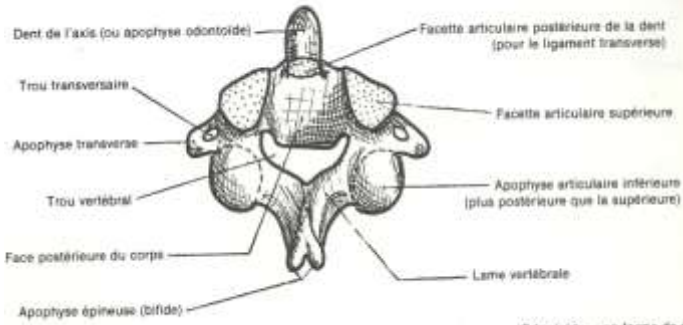
GUIDES DES VERTEBRES THORACIQUES (MOUVEMENTS)



GUIDES DES VERTEBRES LOMBAIRES (ORIENTATION)

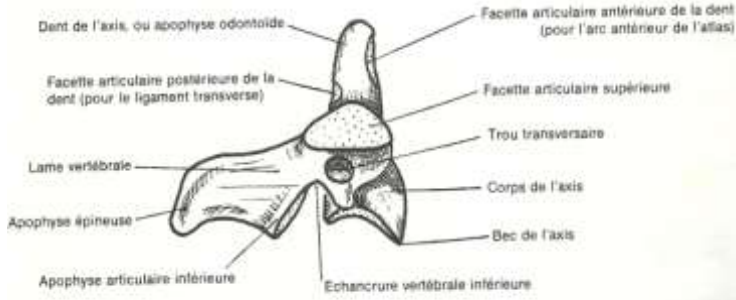


AXIS (SECONDE VERTEBRE CERVICALE)



VUE POSTERO-SUPERIEURE

(Odontoïde = en forme de dent)



VUE LATÉRALE (Noter le décalage des facettes articulaires)

