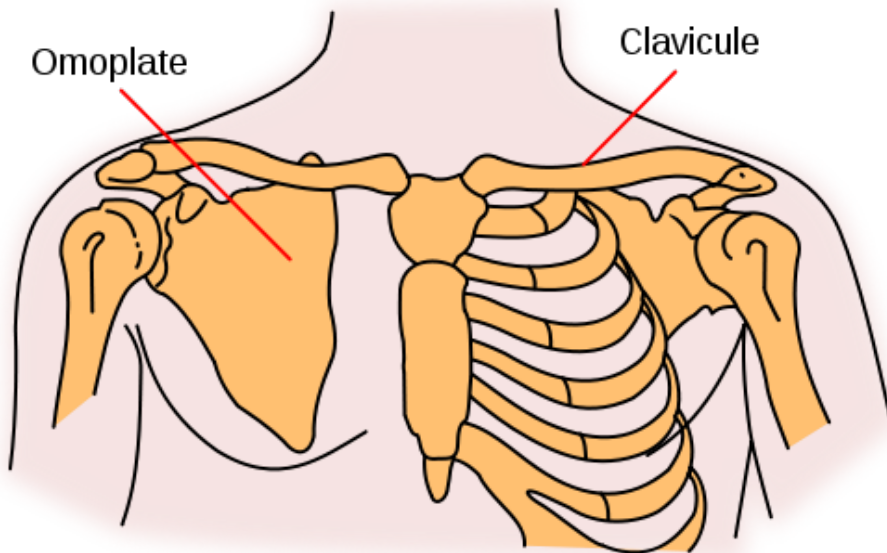
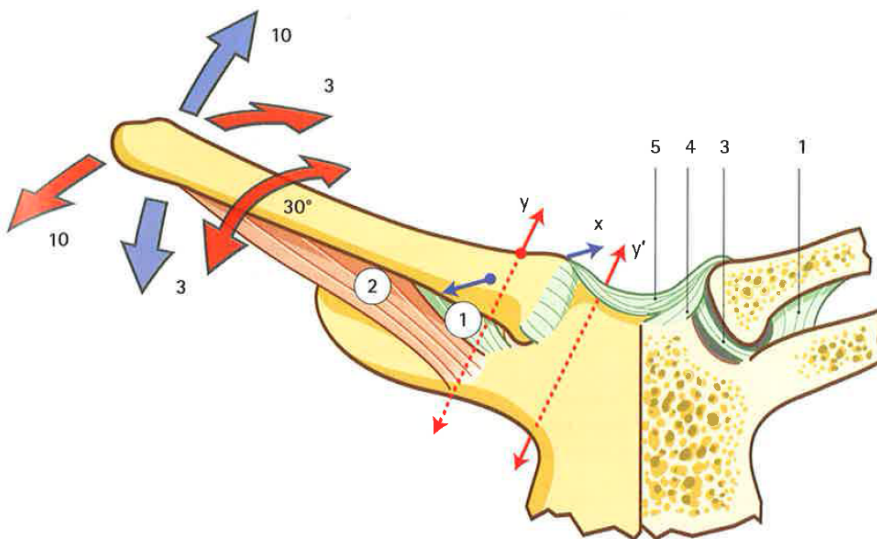


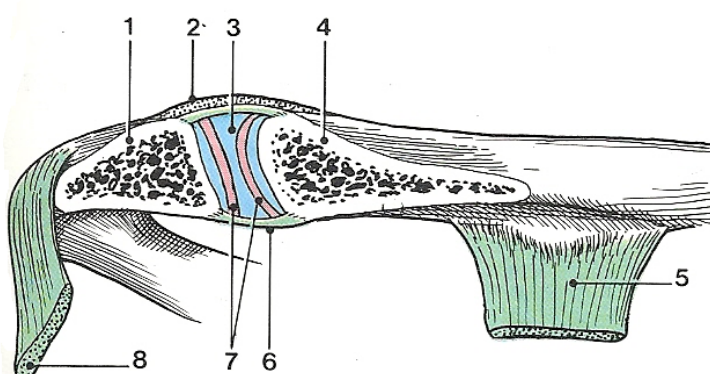
La ceinture scapulaire



L'articulation sterno-costo claviculaire



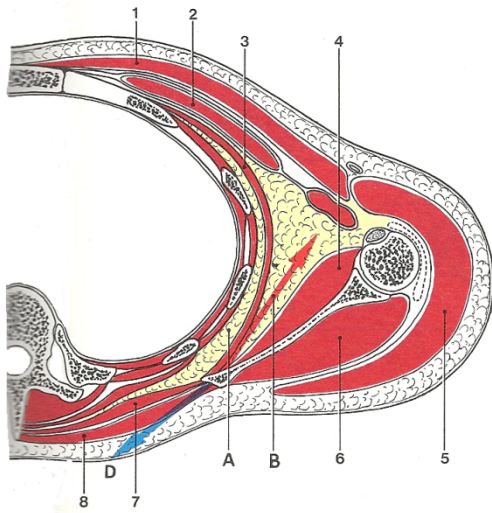
L'articulation acromio-claviculaire



Articulation acromio-claviculaire
(coupe frontale)

- 1 - acromion
- 2 - lig. acromio-claviculaire
- 3 - disque artulaire
- 4 - clavicule
- 5 - ligament conoïde
- 6 - capsule artulaire
- 7 - cavité artulaire
- 8 - lig. coraco-acromial

L'articulation scapulo-thoracique ou omo-serrato-thoracique

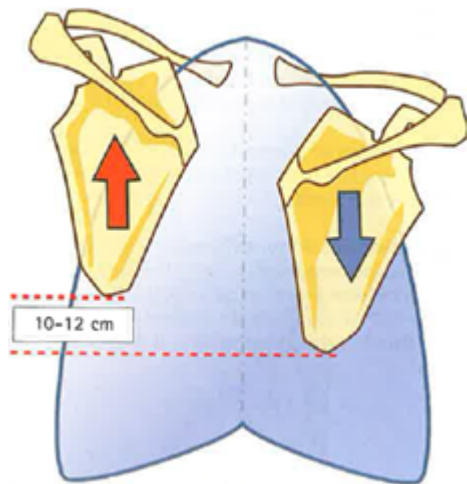
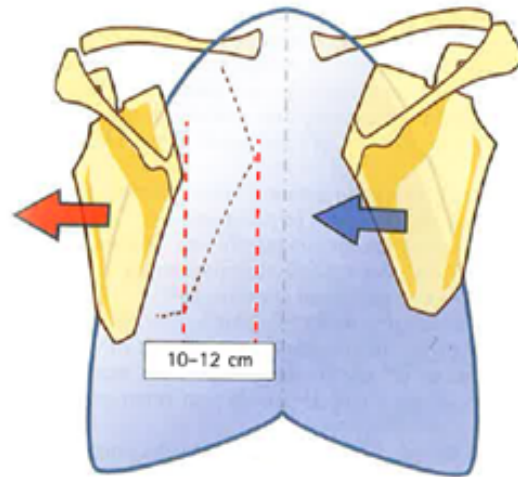


Syssarcoses scapulo-thoraciques
(coupe horizontale)

- 1 - m. grand pectoral
- 2 - m. petit pectoral
- 3 - m. dentelé ant.
- 4 - m. subscapulaire
- 5 - m. deltoïde
- 6 - m. infra-épineux
- 7 - m. rhomboïde
- 8 - m. trapèze
- A - syssarcose serrato-thoracique
- B - syssarcose serrato-scapulaire

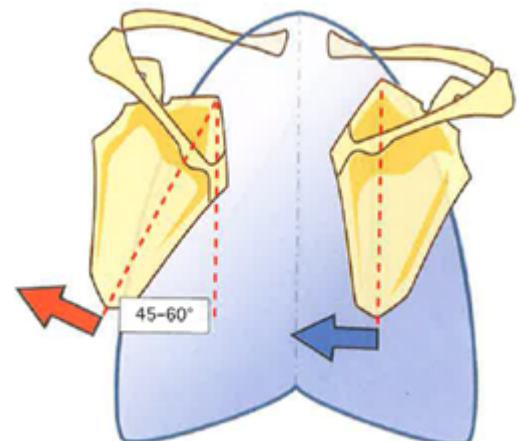
Articulations de la ceinture du membre supérieur

Abduction-adduction

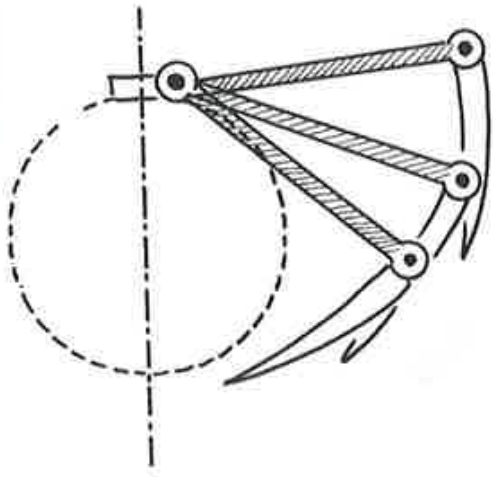


Elévation-abaissement

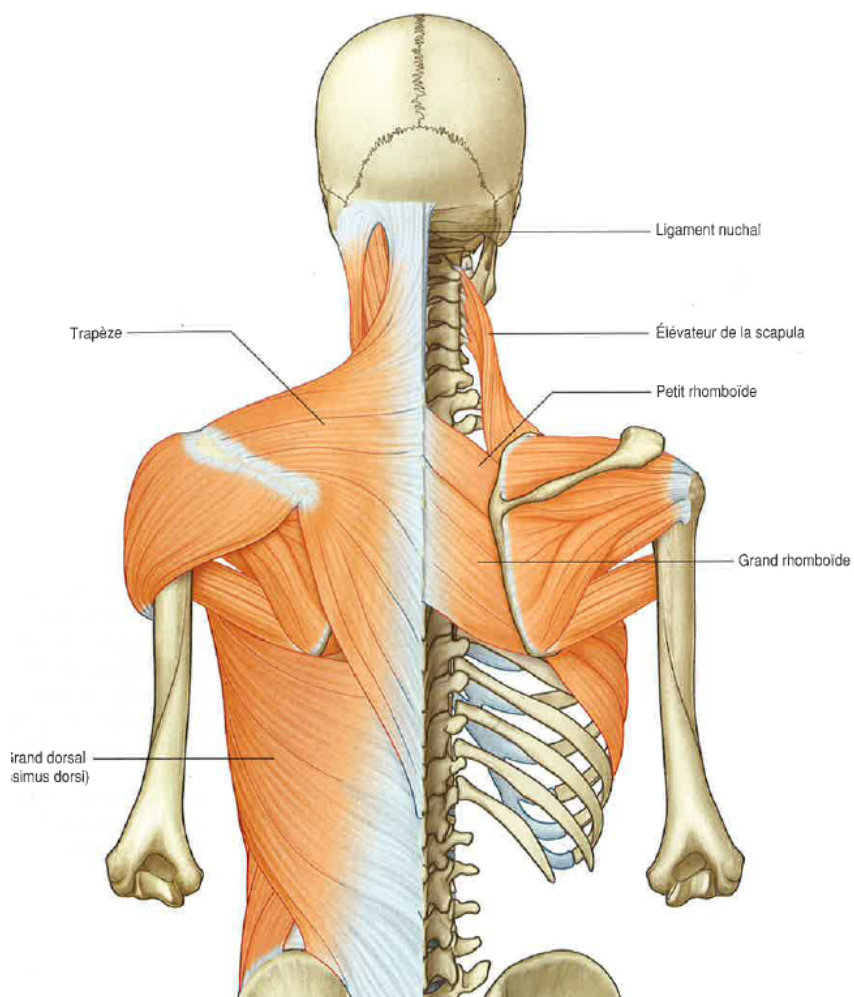
Sonnette médiale-sonnette latérale



La clavicle, biellette de réglage



Les actions musculaires



cran.
↓
caud.

